

The Multitude of Problems Occurring after Whiplash Injury (Symptoms, Diagnosis and Therapy)

1) Abbas Montazem MD* 2) Sayed.Sadi Tavakoli MD

2) Senior Neurosurgeon of Shariati Hospital Isfahan Iran

1) Senior Neurosurgeon of Laleh Hospital in Teheran /Iran

2) Senior Neurosurgeon of Shariati Hospital Isfahan /Iran

3)* Corresponding Autor : Abbas Montazem MD, Senior Neurosurgeon of Laleh Hospital
in Tehran Tel.; 0098 912 817 4719 ,Fax. (Laleh Hospital) 0098 21 8857 1081

E Mail : dr.montazem @gmail.com Home Page : www.montazem.de

Abstract:

Approximately 400,000 whiplash injuries occur each year in Germany.(in percentage the same as in Scandinavia) From these 10% require medical treatment. Instability of the cranio-cervical junction causes distress that can lead to the inability to work. It is often believed that the patient has a psychological problem, or that the patient is trying for social benefits. Misdiagnosing these patients is supported by complex cranio-cephalic symptoms without obvious pathomorphological findings. Knowledge of the typical symptomatology, application of special neurootological examinations, as well as particular imaging techniques is a guarantee for a correct diagnosis. Following conservative treatment a stabilizing operation may be indicated for better quality of life, improved health, and reduction in the consumption of analgesics. The results of surgical stabilization of cranio-cervical junction are encouraging. Instability of the cranio-cervical junction deserves more attention, special examinations should be carried out routinely and the indication for an operation made earlier.

Keywords : Instability-Upper Cervical Joints

This article is to report a phenomenon observed by me through 20 years of practical experience with multitude of suffering patients after whiplash injury

INTRODUCTION

The rising traffic volume in the industrial nations of central Europe is responsible for increasing injuries.

Statistics reveal that whiplash injuries are found in every third accident (1).

Simple whiplash injuries often heal spontaneously. In some cases, however, there are complicated fractures of the vertebrae with or without neurological damages. In these cases, diagnosis is made in the emergency-room without difficulties, and adequate treatment can soon be started.

Some patients, however, might have suffered from a structural instability caused by a torn or an abnormally stretched ligament in a certain part of the neck, and where damaged bones and nerves are not to be found. These injuries can cause lasting symptoms that might not respond to conventional treatment.

It is this group of patients that often have been examined by a variety of specialists and surgeons who cannot find a pathomorphological problem related to the presented symptoms. Due to this discrepancy many patients are referred to psychiatrists as symptoms are not believed with anatomical origin and consequently an emotional imbalance is suspected.

For a number of years we have been involved in the management of these particular patients. Since 1996 we have been offering surgically stabilization of these acquired instabilities of the cranio-cervical junction. Our experience has shown that this form of management has improved the quality of life in the vast majority of our patients (1). Here we would like to share with you the experience of surgical approach which could be offered to patients who have instability of the cranio-cervical junction.

Hypothesis and explanation for Neuro- pathological change after damaging of supportive structures in upper cervical joints

Patients can manifest diverse symptoms which can be classified as cervico-cephalic and cervico-encephalic symptoms. These symptoms are possibly explained by pathological movements in C0/C1/C2 joints produced by rupture of supportive structures of cranio-cervical joints i.e. Allar ligaments, apical ligament, C1/C2 joint capsular ligaments and atlanto-occipital membrane.

It seems that these pathological movements send wrong impulses to the brainstem. One can possibly compare it with a faulty software causing disturbances in the computer. This is why neurological examinations concentrating on the central nervous system, (the hardware), are unremarkable, but disturbances in the brainstem lead to significant symptoms which mostly are subjective. Wrong impulses reaching the brainstem will cause disturbances in vision, audition, balance, taste and smell. These disturbances can vary in intensity from

patient to patient. Occasionally local anaesthetic administered to C₁/C₂ joints can temporarily interrupt these wrong impulses, and can assist in the differential diagnosis.

Cranio-cervical instability is a diagnostic challenge as symptoms frequently do not correlate with routine radiological findings. One has to be aware that employing the correct functional studies will provide an explanation for the symptomatology.

The idea was born to stop movements in upper cervical joint to stop sending wrong impulses to brains stem .An external fixation with halo ring for the first 15 patients was documented with splendid results and all 15 patients wanted to be operated on.

Diagnosis :

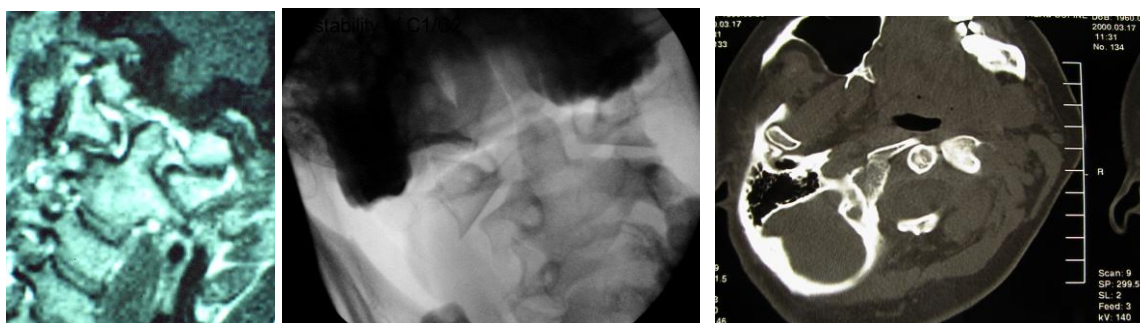
Criteria in diagnosis of cranio-cervical instability syndrome, are based on, typical symptomatology, special neurootological examinations and functional imaging.

Among symptoms, the most important are cognitive problems, loss of concentration, imbalance, gait disturbance, loss of stereogenesis, light headedness, dizziness, tinnitus, hearing loss ,change of hearing quality, blurred vision ,night blindness, change of visual quality, visual field defects and even complete blindness .Other common symptoms are dysesthesia and loss of hand dexterity.

Neurological examinations focussed on vision, audition, taste and smell.

Objective analysis of the head's movement was performed with craniocorpography. Light sources were fixed to the head and shoulders in early stages of this technique. Now functional images of the human's equilibrium were obtained with computerized ultrasonic craniocorpography (2). For a correct and informative assessment of the injured cranio-cervical joint, imaging techniques were employed. These consisted of functional conventional x-rays of C0/C₁/C₂, functional CT scans of the upper cervical spine, functional fluoroscopic analysis of the cervical spine and functional MRI scans of the cranio-cervical junction (3.).

Fig.1 rupture of left allar lig. Fig 2 instability of C1/C2 , Fig.3 Dens dislocation in CT



There are different preferred methods for diagnosing of C0/C1/C2 instability. We believe that functional study by fluoroscopy (C-Arm) can provide the best information and We have never made the final decision for surgery in lag of definite fluoroscopic evidences.

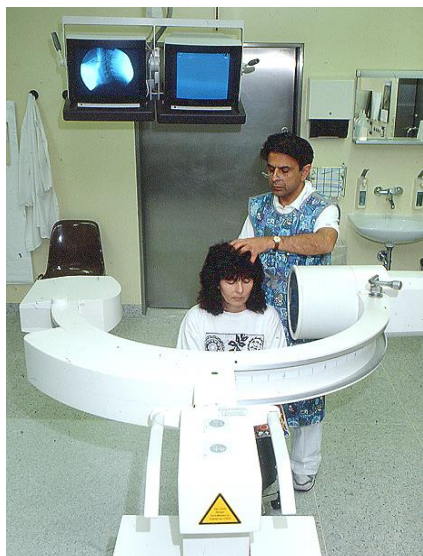

Fig.4 Functional study by C-arm

Treatment:

A) Non surgical Treatment:

- 1) Manual atlas therapy by Arlene (trying to give atlas a better geometrical position and better muscular support).
- 2) Conventional manual therapy.
- 3) Cranio-sacral therapy (try to change impulse sending to brain stem).
- 4) Neuro muscular trainings therapy. (try to change impulse sending to brain stem).

B) Interventional Treatment :

Radio frequency therapy : using fine electrode to reach spinal nerves, facet joints and some part of vegetative nerves and giving radio frequency impulses.

(try to reset impulse sending to brain stem).

Prolotherapy : Using long needle (CT guided) to reach facet joints of C0/C1 and C1/ C2 and apply special substances for inducing cell proliferation in facet joint area to produce secondary partial stabilisation and as a result, stop sending wrong impulses from neck area to the brainstem.(8)

C) Surgical Treatment

History: For decades (from 1950s) surgical stabilization of upper cervical joints (C0/C1/C2) have been performed in rheumatoid arthritis patients who suffered from symptoms similar to whiplash patients, so it is logical to use the same approach for whiplash injury victims suffering from the similar symptoms and have definite radiological findings, and that is how the idea of surgical treatment was born for such patients.

As far as the operation procedures are concerned, obviously the same procedures employed for rheumatoid patients were suggested, that is, using bone graft from iliac crest, screws between C1 and C2 and wiring. This kind of operation, however entailed numerous problems such as osteolysis in the grafted bone, permutation in the geometric positioning of the upper cervical region and finally re-instability. Such problems led to a different surgical approach i.e. beside screws between C1 and C2 and wiring., using a thin titanium plate, as an internal support, which brought about much better results. However, during the follow up observations, it was discovered that about 22% of the thin titanium plates were broken. This problem was subsequently solved by using a thicker plate. Here, it should be mentioned that, before I started stabilizing operations on whiplash injured patients with upper cervical instability resulting from whiplash injuries, 210 patients had been diagnosed as suffering from rheumatoid arthritis and operated on , adopting the usual procedure for stabilization of the upper cervical region..

At a point in time, in all scientific circles in Europe and all orthopaedic and neurological surgery associations, controversial discussions and arguments were raised regarding the above-mentioned operation and their respective approach. As a result, I decided to adopt a new approach in stabilizing the upper cervical region by using only screws and titanium plates between C0 and C3 and transarticular fixation in C1 and C2 without using the bone graft. I also informed the patients that the operation without the bone graft is reversible, meaning that should a need arise at any time, a bone grafting could be done in a second operation.

In all the patients who came within the first 3 months after the operation for a follow- up checking, the control X-ray showed no change in the position of the screws and plates and thus no need for a second operation and introducing a bone graft. It should be mentioned that, from 470 patients who had undergone the stabilization operation, only 11 patients referred to receive a second operation for bone grafting.

Surgical procedure:

Surgery was performed with conventional full anaesthesia. Patients were laid in prone position with the face down; the head was tilted ventrally and supported (Fig. 6)

An x-ray monitor was draped and placed into position.

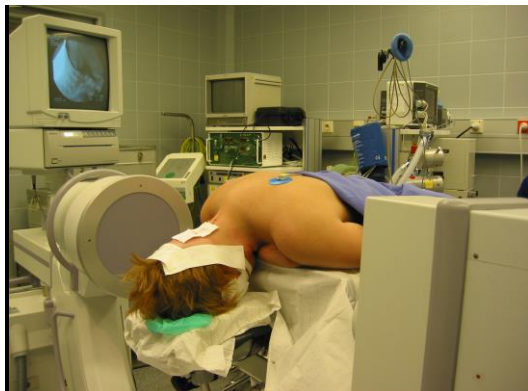

Fig.6 : Patient position

The incision was made along the dorsal midline passing over the cranio-cervical junction. The incision extended precisely in the midline along the linea nuchae from the occipital protuberance to the dorsal process of C₆ (Fig. 7).

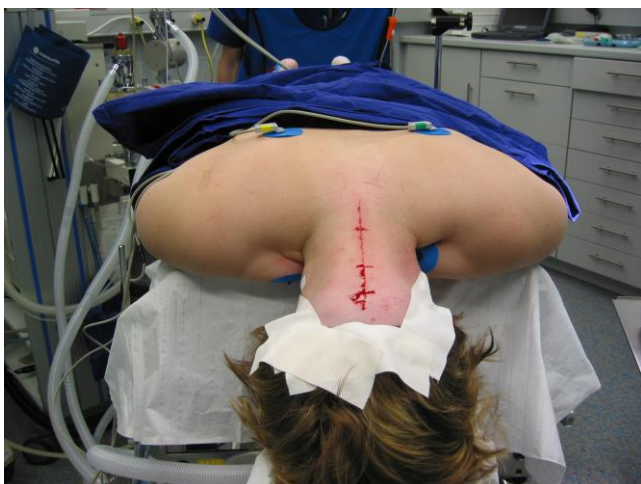

Fig.7 Midline incision

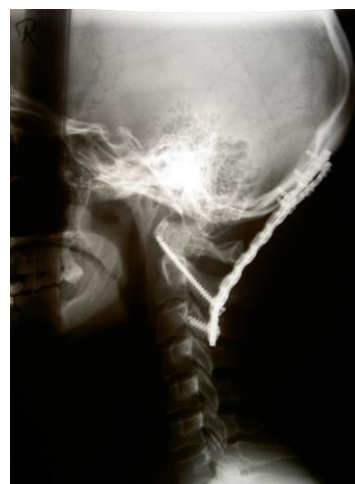

Fig.8 Post Op. X-ray

Here, I don't find it necessary to present the procedures of the surgery in detail.

A trans-articular screw with a length of 40mm supported the C₁/C₂ joint. The titanium plate stabilized the C₃ joint too. This solid unit between C₀/C₁/C₂ up to C₃ prevented any adverse movements. After surgery a lateral x-ray of the upper neck was taken to demonstrate bone structures and the implant (Fig. 8).

PATIENTS

From 1985 to 2007 , 543 patients were operated on, with the diagnosis of instability in the upper cervical joints. Of these patients, 219 cases, rheumatoid arthritis was the cause of the instability and a fusion was always done for them using a bone graft from iliac- crest. But this group of patients is not the object of this article. I only made a reference to these patients because they were also suffering from the same symptoms as whiplash patients.

More importantly, because good experience was gained from this procedure for R.A .patients and that was the fact that, regardless of what the cause of instability in the upper cervical joints, stabilization operation would either alleviate or totally eliminate the painful and discomforting symptoms. Of these 324 patients operated on, 145 men and the remaining 179 were women; the oldest of the men was 68 years old. Not all the patients who suffered severely from instability of upper cervical joints were from Germany. As soon as the news of the possibility of surgical treatment of this problem came to Germany from neighboring countries. I had patients as follows :

Patiens statistic after operation Between 1994 and 2006

Number of patients	Country of origin	cause of problem.....	Nr.
122	Germany	Os odontoid	4
4	Belgium	car accident	174
21	Iran	Hard Sport	93
8	Italy	Home accident	48
69	Norway	unknown cause	5
85	Sweden		
324	Total.	Total	324

In all our patients the diagnosis of instability was confirmed at the time of surgery. Not in all injuries, however, findings were the same. Most of cases revealed a combined instability of C0/C1 , C1/C2 and C2/C3 joints and dens subluxation. In 32% a luxation or subluxation in C1/C2 joints was apparent.

All the patients who were operated on by us had received conservative treatment for at least 6 months prior to operation and claimed that the trend of their ailments had taken a worsening course and that they had constantly taken pain-killers. Thus, none of them could work and 124

of them needed a social aid worker in order to do their daily routine requirements. There were many who said that the idea of suicide had often occurred in their minds. So, the patients who were operated on by us were the ones who decided to undergo a surgical operation as the only choice left to them, in spite of all the risks involved.

RESULTS

Each time that a patient referred to the hospital for a follow-up, beside a clinical check-up, an x-ray examination was also done. Those patients who did not show up regularly for their follow-up exams are not included in the following statistics.

In more than 90% of the patients who suffered from permanent headaches, the pain was totally gone after the operation and in 27% the headache was no longer permanent and was often cured with ordinary pain-killer. The pain was mainly located in the centre of the head and neck and was rather a tension headache. It was often permanent. In addition, pain occasionally spread into the extremities and the body.

In 97% of the patients who suffered from tinnitus, this problem was gone after the operation. All the patients were pleased to find that their cognitive power were improved. Patients with instability of the cranio-cervical junction generally have motor deficits. These were short lived deficits of a variety of motor functions in the area of the head, face, abdomen and extremities. Here and there muscle weakness could be felt in the whole body.

Patients had an altered ability of coordination in the extremities or parts of them that also affected fine motor coordination of the face. This had an effect on facial expression and speech production. Together with motor deficits these coordination disorders caused dysphonia, restriction in breathing and ataxia. 95% of the patients who were afflicted with muscle dysfunction were cured immediately after the operation and their coordination became almost natural. The muscle strength and coordination in 16% of the patients became completely normal. 3 patients, however, needed wheelchairs for moving around.

The combination of motor weakness, coordination difficulties and a disturbed sense of balance caused a breakdown of motor function in some patients. Patients often described a tendency to fall, sometimes falling without an obvious reason. Such falls could lead to more

injuries. Electro-encephalograms had been performed on these patients, but the results were rarely abnormal.

After the operation, these patients did not experience sudden fallings which they had before.

The visual deficits manifested by restriction in the visual field and vision in 78% of patients. Often patients mentioned difficulties to focus, said that after the operation they could again distinguish colours normally and their vision had improved. 32 patients said that a year after the operation, they had no more need for spectacles.

Hearing disorders or tinnitus were present in 81% of patients. It could affect one or both ears, and the hearing deficit was invariably associated with tinnitus. Tinnitus in different patients came in different range of strength .I know a patient who suffered so much from this phenomenon that had thought of committing suicide. All patients who suffered from tinnitus as a result of accident were relieved after the surgical operation. There were , however, 7 patients who said that the noise still persisted after the operation, but with a tolerable strength.

Dysosmia and dysgeusia were found in 26% of patients. This was a general hypersensitivity or an altered quality of perception. Dysosmia or hypergeusia had often been incorrectly diagnosed an allergic reaction. This patients were ,after the operation, wonderfully relieved of the problem and stopped taking the antialergic medication. Following surgery 85 % of our patients stated that their quality of life had improved. Of these 40% were able to go back to work. A permanent intake of analgesics could be stopped in 74% of cases ,and in some cases the need was from time to time.

In addition to these symptoms the majority of patients were unable to tolerate any physical load. Typically many patients complained of poor concentration since the injury. Patients themselves located their instability to the junction of the head and neck. Pain not responding to any form of analgesics was a common finding. While 85% of the patients clearly stated that surgery had significantly improved their quality of life, 15% of patients stated that surgery had not fulfilled their expectations.

Complications

- 1) While operating: Only in 15 cases of all operations, venal bleeding occurred while perforating between C1/C2 , which was quickly stopped. In 12 cases, spinal fluid was leaking while perforating the cranium for fixing the plate and screws, which was again quickly remedied.
- 2) Up to 4 weeks after the operation : in 17 cases, superficial infection in the operated surface within the second week of operation was added, which was remedied with anti-biotic.

3) Late complications : (up to one year after operation) . In 24 cases, rotation of the head had diminished to only 10% of the normal. It should be noted that the head rotation generally becomes somewhat limited as compared to what it was before the operation.

In addition we have seen the following side effects: in 16% the screw fixed to the occiput weakened, in 13% the titanium plate fractured (old operation method), in one case a screw at C₁/C₂ was bent from physiotherapy, and in one case subarachnoid haemorrhage was seen. Severe and life threatening complications were not observed. There was a vast variety in the reduction of head mobility following surgery. This range of restriction with a changed bio-mechanism of the neck was well accepted.

Control Group:

Between 1994 and 2006, a great number of patients who were suffering from instability in the upper cervical region resulting from whiplash injuries came to me and in spite of the fact that I suggested surgical operation, they refused to be operated on for various reason.54 of these patients, however, agreed to come back to me, at least once a year, for a follow up. Thus I had the chance to be in contact with these patient and get to know the progression of their ailment.

31 of the these patients told me that their discomfort had become somewhat more severe every year. 27 of them reported that new symptoms had been added to those they had had before. These latter group said they were not able to work and 14 patients needed help from social workers etc. in order to be able to do their daily house chores.

Of the 54 patients mentioned above, there remains 23 of whom19 reported that their situation hadn't changed during the years and conservative treatment had brought about no changes.

Only 10 patients of these were engaged in part-time work. 4 patients were enjoying relative improvements and work on a half-day basis.

All of the control group said that they were using analgesics either regularly or intermittently.

14 patients had been regularly under treatment in a pain clinic, receiving synthetic morphine patches. Questionnaires were devised and sent to all 54 patients individually at the beginning of 2006.Up to April of the same year, 51 questionnaires were completed and returned to us.(These were the patients that had decided not to undergo surgical operation for various reason). They all had said that their life quality; as compared with that before the accident, had deteriorated by 50 to 80 percent. In 41 cases, family relationships had worsened, because

of the ailment of one party, sometimes resulting in separation and even divorce and losing mutual friends.

DISCUSSION AND Conclusion

In the 1950ies improved anaesthetics and development of new surgical instruments made surgery at the cranio-cervical junction possible. The main indication for surgery was then to decompress the spinal cord and cerebellum in tumour patients. Schilling suggested that juvenile ankylosing spondylitis causes an instability and stenosis at the cranio-cervical junction (4). This was taken up by the neurosurgeon Schürmann who was the first to perform a stabilizing operation at the cranio-cervical junction in a patient with ankylosing spondylitis. In this operation an autologous bone graft from the pelvic crest was taken to fix and decompress the spinal stenosis (4).

In the 1970ies Roy-Camille and Judet reported on a surgical technique to stabilize the fractured cervical spine with screws. This technique involved fixing the arch of C₂ from a dorsal approach and stabilizing the dens from ventral (5). In 1986 Magerl described stabilizing C₁/C₂ from a dorsal approach (6). In 1999 Dvorak and Grob explored modern surgical techniques for stabilizing instability of the middle and lower cervical spine (7).

Instability of the cranio-cervical junction is not necessarily associated with fractures of vertebrae or damaged nerves. This can account for the difficulty to correctly diagnose the condition. A correct diagnosis can also be missed when conventional static imaging techniques are being employed.

It is in the nature of conventional static x-rays that they do not demonstrate changes in important areas of the injured neck. The situation is not improved with CT scans and MRI scans when they are non functional studies. If a patient rests quietly during the x-ray examination, a torn ligament can't be seen. A good example is if we take photo from a man who has a limp in his leg, the photo does not show the limping. But a video film taken from the same man while walking perfectly shows the limp

This group of patients, of course, is continuously searching for advice from doctors, who can't find a morphological correlate for the described symptoms. The situation might still become more difficult, if the patient is of middle age as the area of the middle neck vertebrae shows natural signs of wear and tear. If this is the case, very often the signs of wear and tear are made responsible for the symptomatology, neglecting the fact that the patient didn't have symptoms before the accident.

A diagnosis of instability of the cranio-cervical junction was already established in 95% of our patients before we became involved in the management. Here functional x-ray studies were the norm to get to a diagnosis. However, effective treatments were not offered, and patients continued to explore other forms of management and were desperately seeking help. At the time of surgery all patients had been out of work since the injury and some were dependent and could not function without outside support.

In our series the diagnosis of instability of the cranio-cervical junction was confirmed at the time of surgery. Most of them had a snapped alar ligament, the transverse ligament was not damaged, and instability was made worse through torn capsules at C₁/C₂.

The most useful imaging technique was a functional MRI study of the cranio-cervical junction. Torn ligaments, particularly the alar and transverse ligaments, were easily demonstrated, and the abnormal position of the dens clearly visible. In addition in all of our patients contact between the spinal cord and the transverse ligament and the posterior aspect of the dens could be shown.

The aim of our approach was to stabilize an unstable cranio-cervical junction. Until now it has been impossible to surgically restore the original state of a torn ligament from a ventral approach or to replace a torn transversal ligament. The only possible way was to stabilize the cranio-cervical junction from a dorsal approach, and stabilization had to include the immobilization of the segments C₀/C₁/C₂. Only that could ensure that the vertical and horizontal axes are adjusted correctly, and compression of the spinal cord will not occur during head movement. However, the titanium plate needed to be placed physiologically correct. It is incorrect to believe that wiring C₁ and C₂ arches is sufficient for stabilizing these two vertebrae. The wire will invariably cut through the bone within 6 weeks followed by a secondary instability. This instability will also develop if bone grafts do not heal in and become osteolytic.

Some surgeons tend to use the dorsal process of C₂ for stabilization. Also this is insufficient material for fusion at the cranio-cervical junction for the same reasons. The occipital bone must be incorporated during fusion with bone grafts. This is to avoid tilting, which can reach 10°, and to treat an unstable vertical axis.

Fusing C₁/C₂ with trans-articular screws according to Magerl as the only support is insufficient. These past experiences were taken in account and resulted in stabilizing the cranio-cervical junction with a titanium plate. The stabilization had to include the occiput. A changed bio-mechanism and reduced mobility of the neck, however, had to be accepted as a trade in. This appeared justified with a much improved quality of life and reduced intake of analgesics. In addition many patients were able to return to their work.

Instability of the cranio-cervical junction following a whiplash injury can objectively be diagnosed with special techniques. If conservative treatment fails, better results can be obtained with surgery. The high rate of bone absorption puts the use of bone graft in question. A substantial reduction in head mobility has to be accepted. Stabilizing the cranio-cervical junction at the expense of immobilization should, however, not be our final therapeutic goal.

Aknowledgment

Herby I would like thank Prof. Trond Stokke ,Painclinic in Oslo,Norway,
 Prof. Per Holck Anatomical Department University Oslo Norway
 And my brother Reza Montazem for correct translation of this work.

REFERENCES

- 1) Claussen CF. Das HWS- Schleudertrauma – moderne medizinische Erkenntnisse. Editors: Claussen, Dehler, Montazem, Volle. Uni- med1999
- 2) Claussen CF. Equilibrium research, Equilibrimetry and modern treatment. Elsevier 1998
- 3) Volle E, Montazem A. Strukturdefekt der Ligamenta alaria in der offenen Funktionskernspintomografie. Springer Verlag Aktuelle Medizin 35: 188-193, 1997
- 4) Voth D, Glees P. Diseases in the cranio-cervical junction. Anatomical and pathological aspects and detailed clinical accounts. Editor: Voth and Glees. Co-editor: Schürmann and Schilling. Page 249-259, de Gruyter 1987
- 5) Roy-Camille R, Saillant G, Judet T, Mammoudy P. Traumatismes recent des cinq dernieres vertebres cervicales chez i adulte. Ann Chir 36: 735-744, 1982
- 6) Magerl F. Spondylodesen an der oberen Halswirbelsäule. Acta Chir Aug (Suppl): 43-69, 1986
- 7) Dvorak J, Grob D. Halswirbelsäule. Diagnostik und Therapie. Thieme 1999
- 8) Christopher J. Centeno, MD, James Elliott, MSPT, PhDc, Whitney L. Elkins, MPH, and Michael Freeman, PhD, MPH, D Fluoroscopically Guided Cervical Prolotherapy for Instability with Blinded. Pre and Post Radiographic Reading.c Pain physician,2005;8:67-72,issn 1533-3159